



PATIENT PRESENTING CLINICAL SIGNS

- Sydney Goodwin
- seen by a colleague two days ago for decreased appetite and weight loss
 - lab work demonstrates hepatopathy

SPECIES Abnormal PE/Chem/CBC/UA Results: ALT 564 AST 78 ALP 2097 albumin 2.6

Canine **RADIOGRAPHIC STUDY OF THE THORAX**

Right /left lateral and ventrodorsal views of the thorax totaling 5 images available for review.

BREED **RADIOGRAPHIC FINDINGS**

Leonberger
The cardiac silhouette presents no generalized or chamber enlargement. The vertebral heart score is ~ 9.3. The cardiac silhouette appears to be slightly thin and upright.

SEX The pulmonary fields are within normal limits for age. No evidence of pulmonary nodules, masses, consolidations or infiltrates is observed.

FS

There is no evidence of pleural effusion.

AGE The thoracic wall and diaphragm appear normal.

9yr

The mediastinal structures are considered within normal limits.

INTERPRETED BY No evidence of thoracic lymphadenopathy is detected.

Nele Eley (Ondreka),
DVM Dr. med. vet.,
DipECVDI

Mild gastric aerophagia is seen.

RADIOGRAPHIC DIAGNOSIS

HOSPITAL NAME

Northshore
Veterinary Hospital

- Mild hypovolemia with microcardia
- Slightly under perfused lung
- Otherwise, normal age-related thorax with no evidence of pulmonary masses, nodules or other thoracic pathology

REFERRING VET

Brita Kiffney

INTERPRETATION OF FINDINGS & FURTHER RECOMMENDATIONS

The thoracic radiographs in this patient are within age-related normal limits with the exception of subtle signs consistent with hypovolemia which may correlate with decreased appetite and potential systemic illness.

INVOICE

23697

No pulmonary masses or nodules were identified, which is important in conjunction with a history of hepatopathy and weight loss. Thoracic metastatic disease is not evident radiographically.

DATE

01/28/2026



PATIENT

Sydney Goodwin

SPECIES

Canine

BREED

Leonberger

SEX

FS

AGE

9yr

INTERPRETED BY

Nele Eley (Ondreka),
DVM Dr. med. vet.,
DipECVDI

HOSPITAL NAME

Northshore
Veterinary Hospital

REFERRING VET

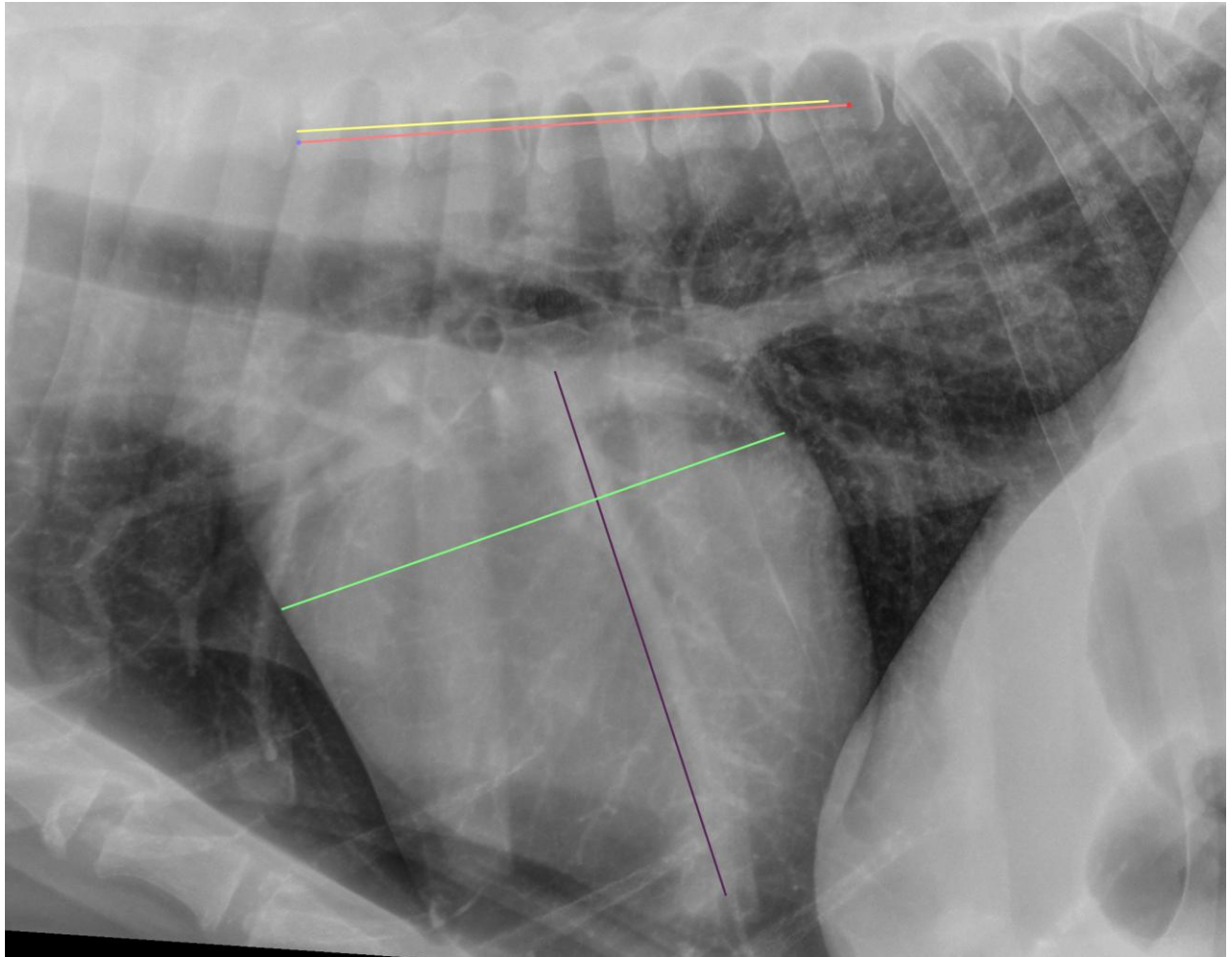
Brita Kiffney

INVOICE

23697

DATE

01/28/2026





PATIENT

Sydney Goodwin

The information and recommendations provided are based on the images presented by the referring veterinarian. No evaluation can be communicated regarding pathology that was not visible in the image/video clips provided.

SPECIES

Canine

Thank you for this referral. If the clinical or image interpretation does not parallel your findings or if I can be of any further assistance please contact me.

BREED

Leonberger

Nele Eley (Ondreka), DVM, Dr. med. vet., DipECVDI
European Specialist in Veterinary Diagnostic Imaging, Cert. Radiology,
Senior lecturer University of Giessen/Germany, Veterinary Faculty, Department of Radiology.
info@sonopath.com

SEX

FS

AGE

9yr

INTERPRETED BY

Nele Eley (Ondreka),
DVM Dr. med. vet.,
DipECVDI

HOSPITAL NAME

Northshore
Veterinary Hospital

REFERRING VET

Brita Kiffney

INVOICE

23697

DATE

01/28/2026